

Severe headache as the only symptom of long-standing shunt dysfunction in hydrocephalic children with normal or slit ventricles revealed by computed tomography

B. DAHLERUP¹, F. GJERRIS²

A. HARMSEN¹ and

P. SOELBERG SØRENSEN²

¹University Clinics of Neurosurgery,
Rigshospitalet, DK-2 100 Copenhagen, Denmark

²University Clinic of Neurosurgery,
Copenhagen County Hospital, DK-2600 Glostrup, Denmark

Abstract. Four patients aged 11, 11, 8 and 18 years, shunted in early childhood for hydrocephalus, were followed in the outpatient clinic for severe headache from 3 months to 2 years. The headache lasted for days and up to a week, was usually severe, and was often followed by screaming attacks or aggressive behavior. In all patients repeated computed tomography disclosed a normal ventricular system or slit ventricles. The intracranial pressure (ICP) was measured in all four patients and showed an increased intracranial steady-state pressure between 20-50 mmHg, plateau waves and, in two of the patients, a very high intracranial pulse-pressure amplitude. At operation all patients had dysfunction of the shunt (most often of the distal end). In three patients ICP monitoring postoperatively showed normal intracranial pressure without any abnormal increments from the normal steady-state pressure. Thus, severe headache can be the only symptom of long-standing shunt dysfunction, even without ventricular dilation. In shunted hydrocephalic children complaining of headaches, ICP measurement is highly recommended.

Key words: Severe headache - Increased intracranial pressure - Intracranial compliance - Hydrocephalus - Slit ventricles - Shunt dysfunction - Computed tomography.

Shunt dysfunction is a well-known complication in treated hydrocephalic children. Depending on the size of the ventricular system, symptoms and signs of dysfunction appear slowly or more rapidly. Many children show symptoms of dysfunction over weeks or months, and most often these children have progressing ventricular dilation on computed tomography (CT). Other children develop acute symptoms with severe headache, vomiting and signs of transtentorial herniation and only slight of the ventricular system on CT. It is commonly found that patients with a small ventricular system, or slit ventricles, on CT often show a tendency to have very acute symptoms and signs of increased intracranial pressure (ICP) [2, 8].

During the last 2 years, we have seen four previously shunted hydrocephalic children with repeated severe attacks of bitemporal or bifrontal headache as the only symptom of severe shunt dysfunction and without ventricular dilation on CT.

CASE REPORTS

CASE 1

An 11-year-old girl with a Dandy-Walker malformation and severe hydrocephalus had a ventriculoatrial shunt placed shortly after birth. The shunt was revised several times (Table 1). At the age of 9 years a second catheter was placed in the trapped fourth ventricle and communicated to the shunt. During 1,5-2 years prior to admission the patient had suffered severe attacks of headache, which lasted up to 1-1,5 months with varying intensity from attack to attack. The headache was always bifrontal, periodically accompanied by drowsiness. After such a period the patient could be without any symptoms for 1-2 weeks, but the headache always returned. Migraine was suspected, but different drugs had no effect. Repeated CT scans revealed slit ventricles. Because of the increasing frequency and intensity of the headache, the epidural pressure was monitored.

CASE 2

An 11-year-old girl with congenital communicating hydrocephalus had a ventriculoatrial shunt placed at the age of 5 months. The shunt was revised twice within the first year. After the last revision she was well until 9-12 months prior to this admission, when she began to complain of daily headache, which was aggravated by any kind of physical exercise and even reading (Table 1). A CT scan revealed small ventricles. After admission, the patient suffered intermittent attacks of unconsciousness. Ophthalmoscopy showed papilledema and a new CT scan showed no change. The intraventricular pressure was monitored.

CASE 3

An 8-year-old boy had had a ventriculoatrial shunt operation when 17 days old for communicating hydrocephalus following a subarachnoid hemorrhage. The shunt was revised many times until the age of 6 years (Table 1), when the boy gradually developed attacks of severe headache accompanied by screaming attacks and aggressive behavior. Repeated CT scans showed slit ventricles. On admission he had no papilledema and the epidural pressure was monitored.

CASE 4

An 18-year-old boy had had a ventriculoatrial shunt operation at age 3 months for communicating hydrocephalus. The shunt was revised several times (Table 1). Five years before this admission the shunt was revised four times, finally with a Pudenz ventriculoperitoneal system.

Table 1. Age, sex and classification of hydrocephalus and shunt operation in four hydrocephalic patients with normal or slit ventricles on CT.

Case no.	Age (years)	Sex	Classification of hydrocephalus	Shunt operation			
				Age at primary operation	Revisions	Age at last revision	Shunt type
1	11	F	Dandy-Walker	1 month	Several times	9 years	Pudenz V-A
2	11	F	Communicating hydrocephalus	5 months	Several times	9 years	Pudenz V-A
3	8	M	Communicating hydrocephalus after subarachnoid hemorrhage	1 month	Several times	6 years	Pudenz V-A
4	18	M	Communicating hydrocephalus	3 months	Several times	13 years	Pudenz V-P

Table 2. History of headache and ICP monitoring preoperatively and postoperatively in four hydrocephalic patients with normal or slit ventricles on CT.

Case no.	Length of history of headache	ICP monitoring (mmHg)				Follow-up
		Before operation		After operation		
		Steady-state	Increments	Steady-state	Increments	
1	1½ – 2 years	50	A-waves B-waves	Normal	0 0	Well
2	9 – 12 months + papiloedema	25	A-waves B-waves (90%)	Not measured		Well
3	2 years	30	A-waves (80 mmHg) B-waves (100%)	Normal	0 0	Well
4	9 months	20	A-waves B-waves	Normal	0 0	Well

One year before admission he developed intermittent headache, mostly bifrontal, and the day before admission he had an attack of severe headache and vomiting. Several CT scans were normal and, on admission, CT again showed a normal ventricular system and normal cortical sulci. The epidural pressure was monitored.

RESULTS

In the first patient the intracranial steady-state pressure was 50 mmHg with B-waves 80% of the monitoring time. Plateau waves of 80 mmHg lasting 8-10 min were noted during the night (Fig. 1). During the plateau waves the patient awoke, complaining of headache. At operation for shunt revision the peritoneal end was found to be occluded. Postoperatively the headache disappeared and epidural measurement showed normal ICP. At follow-up after 6 months the child was well (Table 2).

In the *second* patient the intraventricular pressure was elevated with a mean steady-state pressure of 25 mmHg; plateau waves of 30 mmHg were present and B-waves were seen 90% of the monitoring time. After shunt revision the headache disappeared and at 1-year follow-up she was well (Table 2).

In the *third* patient the intracranial steady-state pressure was elevated to a mean value of 30 mmHg. During attacks of headache the ICP rose to 80 mmHg (Fig. 2). At shunt revision the ventricular catheter was found to be occluded. The intracranial pulse-pressure amplitude was very high and near the blood pressure pulse amplitude. There was continuous B-wave activity. Postoperative ICP monitoring showed normal pressure. The patient was well at follow-up after 6 months (Table 2).

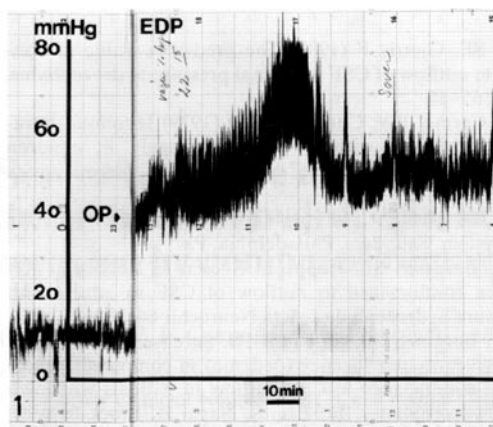


Fig. 1. Epidural pressure measurement in case 1. The mean steady-state pressure for 24 h is 50 mmHg, and the plateau wave is demonstrated. The arrow shows the time of operation, and the left part of the figure shows postoperative ICP measurement. The figure should be read from right to left.

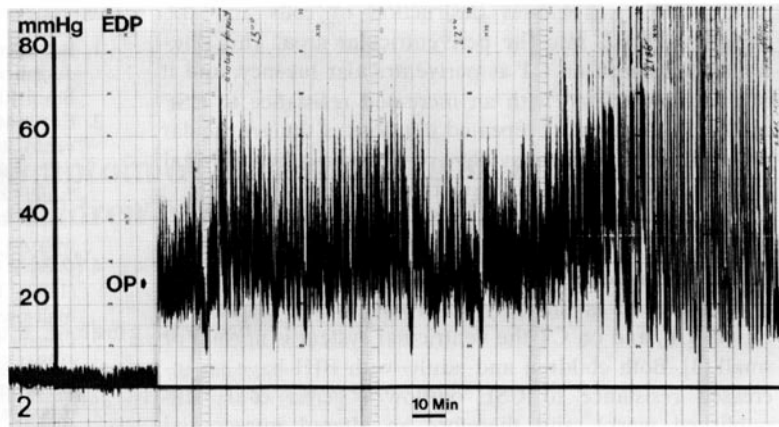


Fig. 2. Epidural measurement of ICP in case 3. Note the very high pulse-pressure amplitude and B-waves. The arrow shows the time of operation and the left side of the figure shows postoperative ICP monitoring. The figure should be read from right to left.

In the *fourth* patient the intracranial steady-state pressure was elevated with a mean value of 20 mmHg. During the night, the patient had plateau waves. B-waves were seen more than 50% of the monitoring time. At shunt revision the peritoneal end was found to be occluded. Postoperative ICP monitoring showed normal pressure and the patient was well at follow-up after 3 months (Table 2).

DISCUSSION

The present study shows that severe headache can be the only symptom of increased ICP caused by shunt dysfunction in previously shunted hydrocephalic children, who on CT have normal or even small ventricles. In childhood severe headache is uncommon, and persistent headache should always be taken seriously [9]. In our four patients, the headache lasted from several months up to 2 years, and three of the patients had intermittent headache only with short intervals of remission, which is an uncommon presenting feature of increased ICP [9]. In children with headache caused by increased ICP the condition is usually associated with other symptoms or an abnormal CT, but in our patients CT showed normal or small ventricles. A normal or even small ventricular system in a hydrocephalic child shunted earlier is considered as a sign of normal shunt function, especially when the child has no symptoms or signs of increased ICP.

Three of our patients had slit ventricles, a term mostly used by radiologists as an indication of shunt dependency. The majority of hydrocephalic children with slit ventricles after shunting are clinically well [6], but occasionally the syndrome may be associated with headache, vomiting, and dizziness, symptoms which might be indistinguishable from those of raised ICP. The syndrome of shunt dependency has many eponyms: slit ventricle syndrome, hydrocephalus without ventriculomegaly or normal volume hydrocephalus [2, 8]. However, there is no agreement that slit ventricles are an abnormal sign since most of the children are quite normal [6].

The slit ventricles and the slit ventricle syndrome may be caused by the siphoning effect of the shunt [7] in patients with impaired transportation or absorption of CSF [1, 3]. There is no agreement as to whether slit ventricles are more common in patients with ventriculoperitoneal shunts than in patients with ventriculoatrial shunts.

The findings of raised ICP and plateau waves indicate an increased resistance to CSF outflow and are in accordance with the findings in high-pressure hydrocephalus [4]. Usually, shunted hydrocephalic patients dilate their ventricular system when they develop shunt dysfunction. This is commonly seen in patients followed up by repeat CT and also in patients developing acute symptoms of increased ICP. The question is why our four patients did not dilate their ventricular system? All the patients were shunted in childhood and had many revisions within the first years of life. When the ventricular system dilation is caused by an increasing intraventricular pressure, there is a disruption of the ventricular ependyma, allowing CSF to seep out through the ventricular wall into the white matter [10]. This causes destruction of cells and the passage of lipids into the periventricular area. This phenomenon is seen on CT as periventricular lucency, and it is always associated with an increased resistance to CSF outflow [5]. The many repeated dilations of the ventricular system in our patients may have provoked a subependymal gliosis, resulting in an increased brain stiffness.

Another condition with points of resemblance to our patients is benign intracranial hypertension (BIH) or pseudotumor cerebri. Patients with BIH usually present with headache as the only or predominant symptom of raised ICP, and on CT the ventricular system is normal or small [3]. Both children and adults with BIH have an increased resistance to CSF outflow (Gjerris et al., unpublished work), and therefore an altered intracranial compliance. This combination might be the explanation why the BIH patients do not dilate their ventricular system (Gjerris et al., unpublished work).

In BIH incarceration does not occur, and although the possibility of spatial compensation is nearly exhausted, none of our patients got signs of tentorial herniation, possibly because of the preserved free CSF communication between the ventricular system and the subarachnoid space (Gjerris et al., unpublished work). The explanation why our four patients did not dilate their ventricular system could be the combination of increased resistance to CSF outflow and increased brain stiffness.

In conclusion, in shunted hydrocephalic children severe headache unaccompanied by other symptoms can indicate shunt dysfunction with increased ICP, despite normal or small ventricles on computer tomography.

ACKNOWLEDGEMENT

The authors acknowledge the financial support (FG) from the research foundation of Lundbeck (Lundbeck Fonden).

REFERENCES

- 1) Børgesen SE, Gjerris F (1982) The predictive value of conductance to outflow of CSF in normal pressure hydrocephalus. *Brain* 105:65-86
- 2) Engel M, Carmel PW, Chutorian AM (1979) Increased intraventricular pressure without ventriculomegaly in children with shunts: "Normal volume" hydrocephalus. *Neurosurgery* 5:549-552
- 3) Fishman RA (1980) Cerebrospinal fluid in diseases of the nervous system. Saunders, Philadelphia, Pa
- 4) Gjerris F, Børgesen SE, Hoppe E, Boesen F, Nordenbo AM (1982) The conductance to outflow of CSF in adults with high-pressure hydrocephalus. *Acta Neurochir* 64:59-67
- 5) Gjerris F, Børgesen SE, Sørensen PS, Sørensen SC, Lester J (1984) Periventricular lucency (oedema) in computed tomography and conductance to CSF-outflow in patients with high pressure hydrocephalus. In: Ishii S, Nagai H, Brock M (eds) *Intracranial pressure 5. Proceedings of the 5th International Symposium on Intracranial Pressure, Tokyo 1983*. Springer, Berlin Heidelberg New York, p 914
- 6) Hirayama A (1982) Slit ventricle - a reluctant goal of ventriculoperitoneal shunt. *Monogr Neural Sci* 8:108-111
- 7) Hoffman HJ (1982) Technical problems in shunts. *Monogr Neural Sci* 8:158-169
- 8) Holness RO, Hoffman HJ, Hendrick EB (1979) Subtemporal decompression for the slit-ventricle syndrom after shunting in hydrocephalic children. *Child's Brain* 5:137-144
- 9) Till K (1975) *Paediatric neurosurgery*. Blackwell, Oxford
- 10) Weller RO, Wisniewski H, Shulman K, Terry D (1974) Experimental hydrocephalus in young dogs. Histological and ultrastructural study of the brain tissue damage. *J Neuropathol Exp Neurol* 30:613-626

NOTE ADDED IN PROOF

The reference in the text (Gjerris et al., unpublished work) is now: Gjerris F, Sørensen PS, Vorstrup S, Paulson OB (in press) Intracranial pressure, conductance to cerebrospinal outflow and cerebral blood flow in patients with benign intracranial hypertension (pseudotumor cerebri). *Arm Neurol*

Child's Nervous System, 1985, 1:49-52.

